

Multifunction System MFS diagnosis and treatment table, a basic tool for programmed stimulotherapy

Abstract

The Multifunction System diagnosis table is a tool that helps ensure proper use of the bio-functional devices used in the programmed stimulotherapy treatment protocol. It is primarily used to ensure that the correct diagnosis is made for each patient, including functional disorders (breathing, swallowing and chewing pattern). After reaching a diagnosis, the type of device to be used for treatment must be selected from this table.

Key words: Diagnosis table. Multifunction System MFS. Programmed stimulotherapy.

Introduction

Functional disorders (breathing, swallowing and chewing) have a direct influence on craniofacial growth and eruption patterns of each subject. A large number of malocclusions are caused by an abnormal growth pattern (brachyfacial or dolichofacial) accompanied by impaired development of the dental arches. Only a limited number of malocclusions are caused by local factors, such as agenesis, supernumerary teeth, macrodontia or microdontia, premature tooth loss, trauma, etc., and general or hereditary factors. We are going to look at how oral function disorders affect the etiopathogenesis of malocclusions using the diagnosis table (Table 1).

Problems listed in the Multifunction System diagnosis table and the corresponding corrective device

Snoring

The snoring phenomenon has been difficult to study as the discomfort caused by snoring is subjective and most data are obtained from people close to the sleeping subject. It is an acoustic phenomenon produced by vibration of the soft tissues of the pharynx during inhalation. If we consider the respiratory tract through which air moves, this is formed by rigid walls (such as the bronchii, trachea) in some areas and non-rigid, collapsible tissues in other areas (soft palate, uvula, tonsils, base of tongue, muscles and pharyngeal mucosa, and more specifically, the area that extends from the epiglottis to the choanae)¹.

Therefore, when air flows through a stenosed or collapsible tract (producing narrowing), vibration appears due to the negative pressure in the airway compared to the external pressure. However, the tract's distensibility and speed of airflow must be sufficient. The velopharyngeal sector is where most snoring originates, although there are other structures, as in the case of sleep apnoea, that cause vibration of the pharyngeal structure due to their narrow shape¹.

Snoring can also be defined as respiratory sound generated in the upper airway, without apnoea or hypoventilation, caused by vibration of the pharyngeal tissues. It is a process that can occur in the absence of sleep apnoea, defined in this case as simple snoring, or in the presence of sleep apnoea, in which case the snorer suffers from sleep disturbance with unpleasant consequences².

The device used to resolve this functional disorder is the MFS nasal stimulator (Figure 1), which is a device designed to promote and restore nose breathing. It comprises two tubes made of thermoplastic material joined by a stabilising band, with a flat area that rests against the nasal septum, an outer convex shape that stretches the nasal alae, a tab that stimulates the muscle insertions in the nasal ala and an external rim to prevent the tubes from accidentally hitting against the nose³.

José Durán von Arx¹
Miguel Merino Arends²
Pablo Echarri³
Alberto Carrasco³

¹Chair of Department of Orthodontics at Universidad de Barcelona
²"MFS" Orthodontics Master's Student at Universidad Autónoma de Barcelona

³Orthodontists

Correspondence:
José Durán Von
Arx Maó 29, bajos
08022 Barcelona

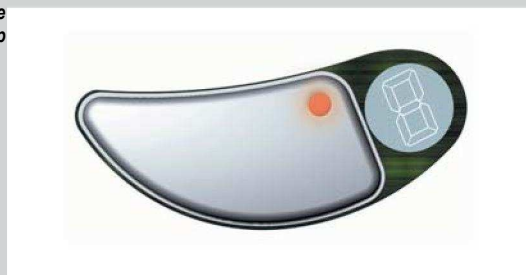Table 1. MFS Diagnosis Table

Snoring		√						
Teeth grinding								√
Brachiofacial pattern							√	√
Overbite								√
Dolichofacial pattern		√	√			√		
Nasal collapse		√						
Adenoids	3-4-5							
Tonsils	3-4-5							
Tongue movement	3-4-5			√	√			
Mouth breathing		√	√					
Lip incompetence			√	√				
Atypical swallowing				√	√			
Open bite					√	√		
Lateral open bite					√	√		
Tongue movement						√		
Perioral contracture							√	

Figure 1. MFS nasal stimulators



Figure 2. Bite strip



Studies conducted show a correction of 81.8% of cases, as reported by the subjects' partners, who noticed great improvements in sleep quality when subjects used the nasal stimulators².

Chewing pattern

This is one of the functional factors that is looked at in most detail in orthodontics as it directly affects the craniofacial architecture, both in terms of increased and decreased muscle tone of the elevator muscles. Clinically it is detected immediately by studying the facial type (brachiofacial, mesofacial or dolichofacial), the mandibular plane angle and morphological features of the gonial angle⁴.

Brachycephalic facial patterns are associated with occlusion and overbite and frequently with teeth grinding⁵. The growth pattern generated by tight elevator muscles of mastication is assessed using cephalometry, which can help determine the extent of deviation of the measured value (Ricketts lower face height angle) from the normal value⁶.

Bruxism, however, can go unnoticed, especially if not accompanied by a "grinding sound" at night. It may be useful to use a bruxism detection system, such as the Bite Strip (Figure 2), a single-use diagnostic instrument. It comprises a microchip with a built-in microelectrode (single-channel electromyogram) and a lithium mini-battery. The patient sticks the Bite Strip to his face, over the masseter muscles, before going to bed. The next morning, the device shows the degree of bruxism recorded on its electronic display, with values of 0 (normal), 1 (limited episodes of bruxism), 2 (moderate bruxism) or 3 (severe bruxism)⁷.

The MFS muscle relaxant (Figure 3) and/or the MFS anti-bruxism device (Figure 4) are indicated for brachycephalic facial patterns. The function of the *muscle relaxants* is predominantly focused on stretching the buccinator muscle, resulting in the relaxing of this muscle group. In turn, the side sections of the device keep the mouth half-open due to the larger vertical dimension of these sections. In a dual-purpose study (subjective and objective) conducted in a sample of patients with bruxism, the clinical effectiveness of these devices was assessed. These devices can also be used, as observed in the table, in all cases of perioral contracture resulting in malocclusion problems. The device is used to relax all the perioral muscles of the masticatory system⁷.

The anti-bruxism devices are in fact a modified version of the muscle relaxants, with the addition of an anterior bite plate to allow anterior contact of the occlusion (incisors) with the plate, thereby preventing occlusal contact with the molars. These devices are specifically designed for patients with bruxism but are also indicated in patients with a reduced lower face height, which is reflected by an increased overbite of the anterior teeth.

Patients with a dolichocephalic facial pattern have a long face with a tendency towards an anterior open bite due to posterior rotation of the mandible⁸. Such patients can be diagnosed by physical examination, although cephalometry is more accurate. On viewing patients' medical records, such patients tend to have a history of mouth breathing and/or common causes of mouth breathing (hypertrophy of adenoids or tonsils)⁹. In these cases, the use of nasal stimulators on their own or in combination with buccal obturators is indicated, as shown in the diagnosis table.

The open bite device (Figure 5) was designed to treat anterior open bite, lateral open bite and/or improve low muscle tone in these patients. In one study conducted in a sample of 22 patients with anterior open bite who used this device at night, a change in anterior open bite measurement from an initial average of 3.432 mm to 2.182 mm at 6 months of treatment was observed. The average result is therefore an open bite correction of 1.25 mm after just 6 months of night-time usage of this pre-fabricated device¹⁰.

The open bite device is also indicated in those cases of functional anterior or lateral open bite associated with tongue thrust swallowing disorders, which prevents eruption of teeth. We therefore use this device as it holds the tongue in a posterior position thanks to the anterior shield of its design.

Lingual buttons used in orthodontics may act as stimuli to raise the tongue towards the palate when swallowing. The design to be used matches buttons supplied by commercial companies. Their function will depend on their position within the patient's mouth³. Therefore, such buttons may be:

- Anterior palatal stimuli, when bonded to the palatal surface of the upper canines or lateral incisors. These cause the tip of the tongue to be raised.

- Posterior palatal stimuli, when bonded to the palatal surface of the upper molars or premolars. These cause the back of the tongue to be raised when swallowing.

Therefore, in order to redirect the tongue away from the open bite, we use lingual buttons as treatment, based on our theory of positive and negative stimuli³.

Mouth breathing

Mouth breathing is a functional disorder related to local factors that prevent air flow through the nostrils¹¹. Nasal collapse, a deviated septum, turbinate hypertrophy or functional alar collapse are causes of mouth breathing. Hypertrophy of the adenoids or tonsils also restricts air flow through the nasal cavity or oropharynx.

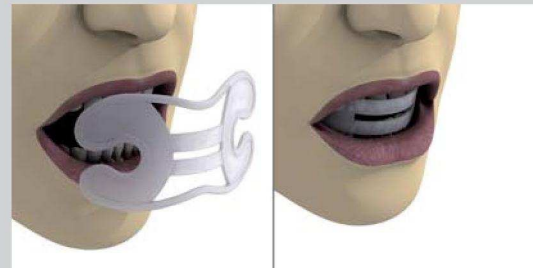


Figure 3.
MFS muscle relaxant

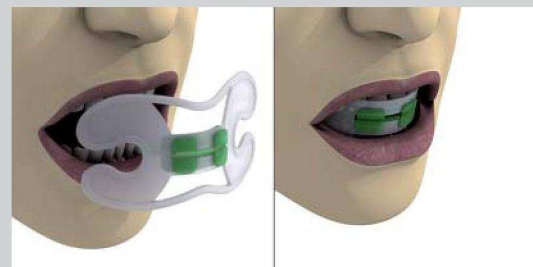


Figure 4.
MFS anti-bruxism

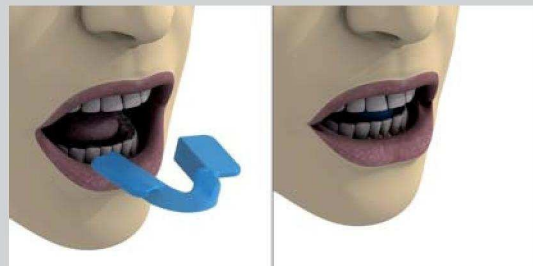


Figure 5.
MFS open bite device

Mouth breathers have common facial features: lip incompetence, short and hypotonic upper lip, everted and hypertonic lower lip, small nose and forward-facing nostrils (Bimler's microrhino dysplasia), posterior-rotated mandible with elongated face (dolichofacial pattern). Mouth breathing promotes development of a class II/1 malocclusion, a low tongue posture (with a tendency of atypical swallowing), and a lax pattern of masticatory muscles¹².

From a cephalometric point of view, mouth breathing first results in posterior rotation of the mandible with retruded mandibular symphysis and then maxillary retrusion as a result of the effect of traction generated by the elongated masticatory muscles. From the morphological point of view, a class II/1 malocclusion develops due to the influence of muscle imbalance on the eruption of teeth, or basically the low tongue posture and its resting position on the teeth of the lateral sectors of the lower dental arch. While the upper molars extrude and mesialise due to the lack of occlusal contact, the lower molars do not erupt due to the tongue resting

on the teeth. Posterior rotation of the mandible, which is initially postural, ends up being effective due to the severe extrusion of the posterior sectors of the upper dental arch. However, while the upper incisors remain in the same position because they rest on the lower lip, the lower incisors extrude and retrude with no blocking factor. In most cases, this results in the appearance of an anterior overbite¹¹.

To treat mouth breathing, the nasal stimulators described above are used with the addition of the MFS buccal obturator (Figure 6), which has three types of permeability: permeable, semi-permeable and impermeable. Buccal obturators are used to seal the mouth and progressively prevent mouth breathing, which is the cause of various malocclusions and also relapse following orthodontic treatment. Buccal obturators are simply shields with a suitable design to fit the shape of the dental arches and progressively prevent air flow through the mouth in mouth breathers. The upper and lower peripheral rim or thickened edge encourages the patient to exercise his lips, which is very important for normalising nose breathing and treating lip incompetence¹³.

Figure 6.
MFS buccal obturator

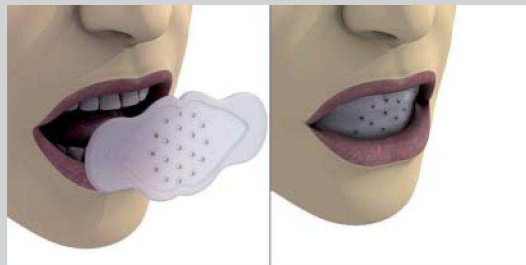

Figure 7.
Grading of nasal collapse

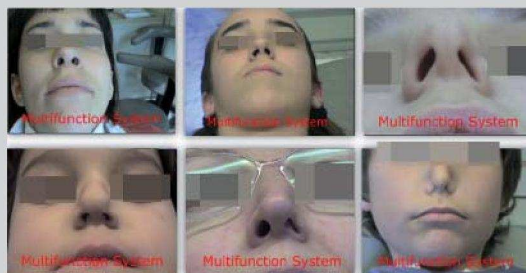
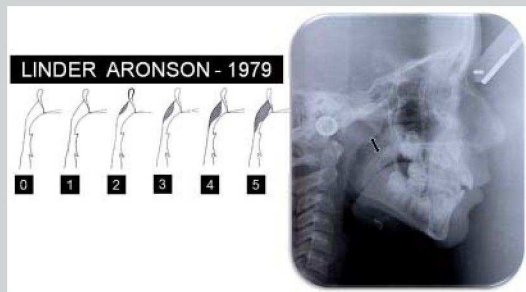
Figure 8.
Grading of hypertrophy of adenoids



Nasal collapse

Nasal collapse is clinically diagnosed by asking the patient to breathe in forcefully through the nose with closed lips. Using an inspiratory effort test, with the patient placed in a situation of extreme respiratory effort (aerobics, sport, jogging, etc.), we can code the nasal collapse (Figure 7) and also the extent to which this problem is related to the mouth breathing habit. Nasal collapse can be coded as follows:

- 0: the patient dilates the nostrils.
- 1: the patient does not dilate the nostrils but does not collapse them.
- 2: a unilateral partial collapse is observed.
- 3: a unilateral total or bilateral partial collapse is observed.
- 4: a total collapse is observed in one nostril and a partial collapse is observed in the other.
- 5: a bilateral total collapse is observed¹⁴.

This coding allows us to identify a nasal disorder that may lead to lip incompetence due to the repetitive nature of the situation. Nasal stimulators were developed to treat nasal collapse during inhalation.

Adenoids

Hypertrophy of the adenoids is diagnosed from lateral X-ray views of the skull and is assessed as follows (Figure 8):

- 0: adenoidectomy performed.
- 1: concave roof and posterior wall in nasopharynx.
- 2: flattened roof and posterior wall.

- 3: roof and posterior wall invading a third of the nasopharyngeal space.
- 4: roof and posterior wall invading two-thirds of the nasopharyngeal space.
- 5: roof and posterior wall invading the entire nasopharyngeal space¹⁴.

The diagnosis table shows the values 3, 4 and 5 in the surgical treatment column and we therefore recommend that all cases with these codes should be referred to an ENT surgeon for an adenoidectomy.

Tonsils

Hypertrophy of the tonsils is diagnosed by direct examination of the oropharynx and codes are given according to the following criteria (Figure 9):

- 0: tonsillectomy performed.
- 1: no tonsils visible.
- 2: tonsils barely visible.
- 3: tonsils invade a third of the oropharynx.
- 4: tonsils invade two-thirds of the oropharynx.
- 5: tonsils completely invade the oropharynx and meet in the middle¹⁴.

Coding the degree of hypertrophy of the tonsils gives us an idea of the patient's capacity to favour mouth breathing or to press the tongue forwards, causing protraction of the tongue, bilabial protrusion, anterior open bite or a class III malocclusion. It will also establish the need for surgery as we can observe that codes 3, 4 and 5 must be referred for a surgical intervention.

Tongue movement

In our MFS study of the tongue, we do not pay much attention to the presence or absence of lingual frenulum but instead focus on the degree of tongue movement as the two factors are not always related. Tongue movement is assessed with the mouth wide open after instructing the patient to touch the ridge behind the upper incisors with the tip of his tongue (Figure 10):

- 0: frenectomy performed.
- 1: the tip of the tongue touches the palate.
- 2: the tip of the tongue almost touches the palate.
- 3: the tip of the tongue is halfway between the upper and lower incisors.
- 4: the tip of the tongue barely gets past the lower incisors.

- 5: the tip of the tongue does not get past the lower incisors. This is called ankyloglossia¹⁴.

Degrees 3, 4 and 5 of tongue movement must be referred for surgery. However, these high values (Table 1) tend to be related to contraction of the upper dental arch as a result of insufficient pressure by the tongue on the palate and the absence of an "expansion" effect by the transverse muscle of the tongue. Such values may also play a role in the development of an open bite or a severe class III malocclusion¹⁵.

Clinical evidence shows that when lingual buttons (Figure 11) are bonded to the teeth, the patient instantly makes a "searching" movement to locate the buttons with the tongue, thereby starting re-education and muscle stretching of the tongue and correcting the initial limitation.

Lip incompetence

Patients with a mouth breathing habit have lip incompetence due to the flow of air through the mouth during breathing as a result of some sort of obstruction in the upper airways. Lip incompetence is one of the most characteristic clinical signs in this group of patients. The loss of contact between the lips inhibits the vertical development of the upper lip, causing it to become shorter over time. The short upper lip leads to a gummy smile and the morphology of the lip is altered, with the philtrum being displaced upwards slightly to form an m-shape¹⁶.

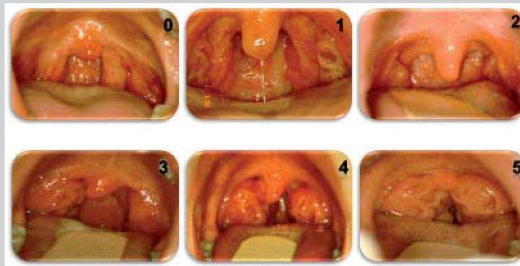


Figure 9.
Coding of hypertrophy of tonsils

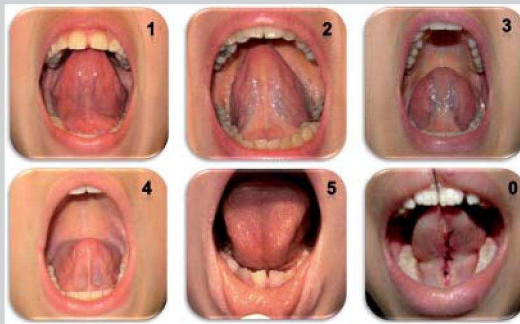


Figure 10.
Coding of tongue movement

To treat lip incontinence, we can recommend the lip stimulator (Figure 12) as shown in the diagnosis table. The lip stimulator is a figure eight-shaped pre-fabricated device with rims on the upper and lower edges that fits towards the rear of the vestibule of the mouth. These rims have a sinuous shape to prevent the device from bumping the upper and lower labial frenula. The patient must use such devices every day when sleeping.

Once in the mouth, the upper and lower sinuous rims of the lip stimulator act on the orbicularis oris muscle, stimulating the lips to extend over the rims. This "extension" of the lips over the fine rims of the device causes the lips to lengthen and draw together¹⁶. Constant lip exercise is the result of the permanent action of the "lip stimulator", creating "automated stimulation" whenever the patient has the device in his mouth.

Atypical swallowing

Atypical swallowing is an archetype of swallowing that reminds us of the immature swallowing pattern. There are many different causes of atypical swallowing but the most common are: the aforementioned class II/1 malocclusion, limited tongue movement (MFS codes 3, 4 and 5)¹⁴, hypertrophy of the tonsils (MFS codes 3, 4 and 5)¹⁴, and mouth breathing itself.

Atypical swallowing, accompanied by a low tongue posture and/or a habit of tongue thrusting, may cause different types of malocclusions, according to the area of pressure¹⁵. It can make overjet in a pre-existing class II/1 malocclusion worse (due to lower lip interposition between the incisors during atypical swallowing) and can also cause an anterior open bite (due to pressure between the dental arches on the incisal edges of the lower incisors) or a class III malocclusion (due to low pressure conditioned by limited tongue movement).

Atypical swallowing is clinically diagnosed by direct examination of the lips and perioral muscles during the patient's swallowing phase. There are different MFS degrees of atypical swallowing as follows:

- 0: no apparent tension in the lips (normal swallowing).
- 1: slight pressure movement in the lips.
- 2: slight sucking of the lower lip.
- 3: major sucking of the lower lip with movement of the upper lip.
- 4: sucking of the lower lip, movement of the upper lip and perioral muscle contracture.
- 5: sucking of the lower lip, movement of the upper lip and perioral contracture are accompanied by contracture of the chin muscles.

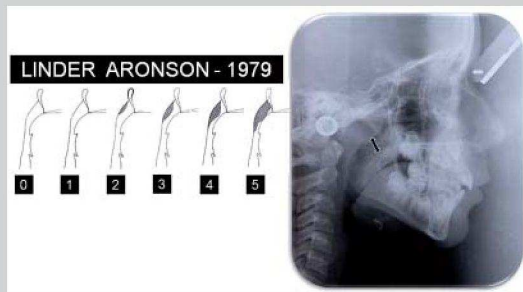
This assessment allows us to determine the severity of the patient's swallowing pattern, which should then be followed by determining the cause(s) of such a pattern. As treatment, we suggest using the lip stimulator at night as shown in the table. We will then use lingual buttons, bonded initially to the upper anterior teeth, to encourage patients to raise the tip of their tongue. Later, we will use lingual buttons in the posterior segment, on the palatal surfaces of premolars or molars, to stimulate patients to raise the back of the tongue.

Figure 11.
Lingual buttons



LINDER ARONSON - 1979

Figure 12.
MFS lip stimulator



LINDER ARONSON - 1979

Clinical use of the MFS diagnosis and treatment table

Having a clinical MFS table to match a patient's functional diagnosis with the most suitable treatment does not mean that a thorough examination is not needed. The table simply means that any dentist can commence programmed stimulotherapy in an easy, efficient way. Based on diagnostic references, the table guides us towards possible MFS devices that may be used to normalise oral functions.

The table not only allows us to determine which devices should be used in each patient but it also allows us to establish the right protocol or sequence for using such devices. Protocols shall be designed according to the MFS devices to be used and their order in the table. Sometimes, different MFS devices may or should be used together at the same time in order to shorten the duration of treatment.

Objectives of programmed stimulothrapy

Programmed stimulothrapy has not been designed to replace the role of functional re-educators, which should still be involved in the interdisciplinary treatment team. The purpose of programmed stimulothrapy is to encourage the patient to use MFS devices every night to perform automated exercises thanks to stimuli generated by the devices³. Myofunctional re-educators should definitely be involved in more complicated cases due partly to non-dental disorders.

However, "programmed stimulothrapy" also aims to make dentists, paediatric dentists and orthodontists more involved in "functionalism" aspects, which is understood to be a normalisation of functions without referring to the clinical use of functional devices, which is more appropriate for qualified specialists.

The programmed stimulothrapy programme may be used in patients with fixed or removable orthodontic devices with the aim of normalising the functional disorder during interceptive or corrective orthodontic treatment.

Programmed stimulothrapy may also be very useful for developing an orthodontics prevention programme protocol, used in this case as a unique treatment to balance oral functions while preventing the development of malocclusions by minimising their etiological factors.

Other specific programmed stimulothrapy programmes include:

- Treatment of snoring.
- Treatment of bruxism (teeth grinding).

Conclusions

It is clear that functional coding allows us to assign disorders a numerical value in order to establish a quantitative diagnosis of the disorder. However, it also guides us toward a possible treatment for the disorder, setting the boundaries between surgery and re-education. We have moved away from a generic diagnosis, avoiding phrases like "the patient has large adenoids or tonsils" or "the patient has lingual frenulum", which do not determine the severity of the problem.

By coding oral functions, we can follow up on each case and assess the changes in such functions, with or without treatment, surgery and/or programmed stimulothrapy. The result is a true analysis of the functional matrix.

If we add specific devices, a treatment protocol, an accurate diagnosis table and subsequent treatment of the diagnosis to this comprehensive functional analysis, we will be one step closer to preventing orthodontic relapses and to achieving simpler, more economic treatments.

Stimulothrapy, automated exercises and clinical usage of such exercises to normalise functions, prevention in orthodontics and treatment of snoring and teeth grinding open new doors for orthodontics.

Bibliography

1. Ustrell J, Durán J. Diagnóstico en ortodoncia. In: Ustrell J, Durán J, editores. *Ortodoncia*. First edition. Barcelona: Ed. Universitat de Barcelona, 2001;61-100.
2. Carrasco A, Durán J, Merino-Arends M. Dilatadores nasales como estímulo para pacientes roncadore; estudio en 55 pacientes. *Ortodoncia Clínica* 2009;12:7-11.
3. Durán J, Carrasco A, Echarri P, Ustrell J, Merino-Arends M. La "estimuloterapia programada" como base para el desarrollo de un protocolo de reeducación funcional oral que nos lleva al concepto de "prevención en ortodoncia". *Dentum* 2008;8:123-9.
4. Durán J. Mecánica "MFS": conceptos clínicos. Control de la sobremordida con los arcos de níquel-titanio con curva reversa. *Ortodoncia Clínica* 2002;6:219-25.
5. Durán J. Tratamiento de las maloclusiones de clase I: apiñamientos moderados, sobremordida y mordida abierta. In: Durán J, editor. *Mecánica fija "MFS". Atlas clínico*. First edition. Barcelona: Ed. Nexus, 2004;53-88.
6. Durán J. Multifunction System "MFS". Las 8 claves de la matriz funcional. *Ortodoncia Clínica* 2003;6:10-3.
7. Durán J, Carrasco A, Echarri P, Ustrell J, Merino-Arends M. Un nuevo elemento prefabricado para relajar la musculatura en los pacientes bruxistas. *Dentum* 2008;8:112-8.
8. Durán J. Biomecánica "MFS" en el tratamiento de las mordidas abiertas esqueléticas. *Ortodoncia Clínica* 2004;7:62-73.
9. Echarri P, Pérez JJ. Historia clínica, examen clínico y estudio de modelos. In: Echarri P, editor. *Diagnóstico en ortodoncia: estudio multidisciplinario*. Barcelona: Ed. Nexus, 2002;57-102.
10. Durán J, Carrasco A, Echarri P, Ustrell J, Merino-Arends M. Cambios clínicos obtenidos con el uso del "aparato para la mordida abierta" MFS en pacientes con mordida abierta anterior. *Dentum* 2008;8:119-22.
11. Durán J. Multifunction System "MFS". Forma y función: puesta al día de la cuestión. *Ortodoncia Clínica* 2003;6:79-88.
12. Durán J, Merino-Arends M, Echarri P. Una nueva propuesta de tratamiento para el paciente con el síndrome de la respiración oral. *Ortodoncia Clínica* 2009;12:73-9.
13. Durán J, Carrasco A, Echarri P, Ustrell J, Merino-Arends M. El obturador bucal "MFS" como un método clínico de tratamiento de la incompetencia labial en los pacientes respiradores bucales. *Dentum* 2008;8:102-7.
14. Durán J. Técnica MFS: Diagnóstico de la matriz funcional: codificación. *Ortodoncia Clínica* 2003;6:138-40.
15. Durán J. Introducción. In: Durán J, editor. *Mecánica fija "MFS". Atlas clínico*. First edition. Barcelona: Ed. Nexus, 2004;31-52.
16. Durán J, Ustrell J, Carrasco A, Echarri P, Merino Arends M. Efectos de los estimuladores labiales a nivel del grado de incompetencia labial y la longitud del labio superior. *Dentum* 2008;8:108-11.